Surgical Dental Extractions

Maria Franco Echevarria, MD, DMD, MSc, FRCDC
Assistant Professor. Undergraduate Program Director
Oral and Maxillofacial Surgery

Faculty of Dentistry
University of Toronto
maria.francoechevarria@utoronto.ca

Objectives

1. Indications
2. Flaps
3. Surgical techniques

Surgical Dental Extractions

Definition

The removal of a tooth achieved with
the use of a soft tissue flap
the removal of surrounding bone
and/or sectioning of it

Surgical Dental Extractions

Indications

Complicated “closed” extraction attempt

Planned open after the initial assessment presence of large cavities/restorations

From the start due to complicated factors – see following slides

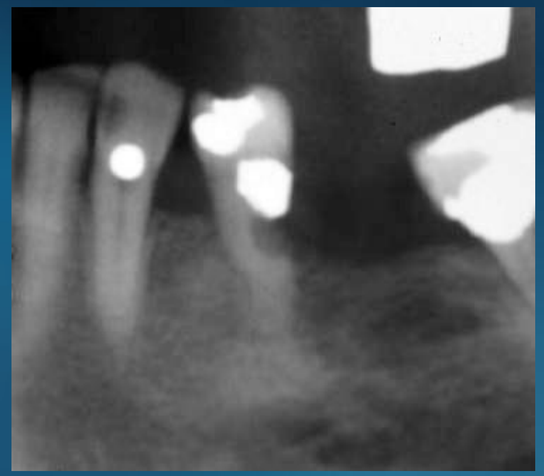

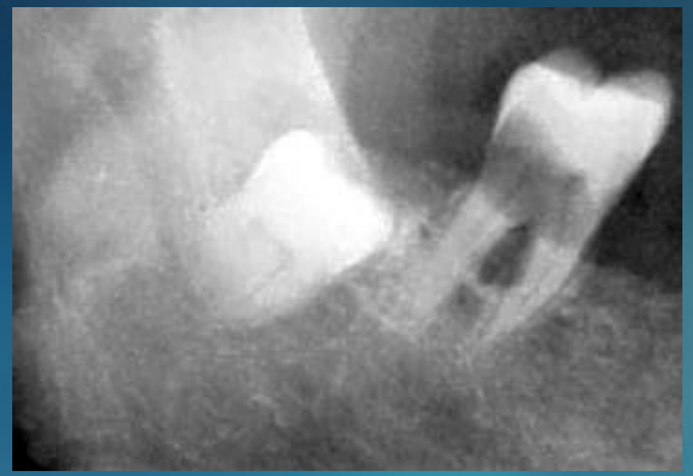

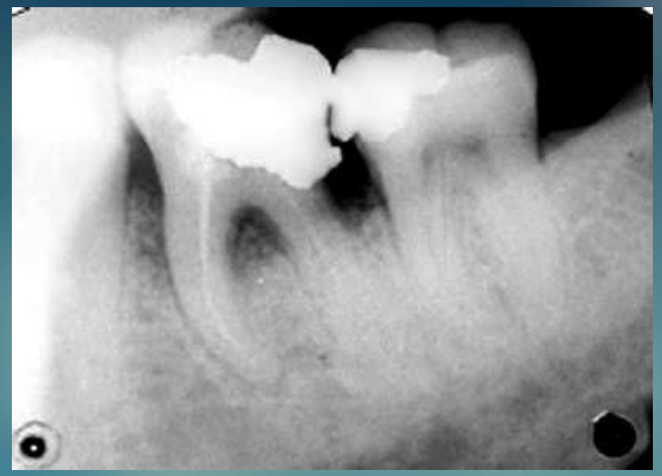

Lack of path of withdrawal

Curved or dilacerated roots

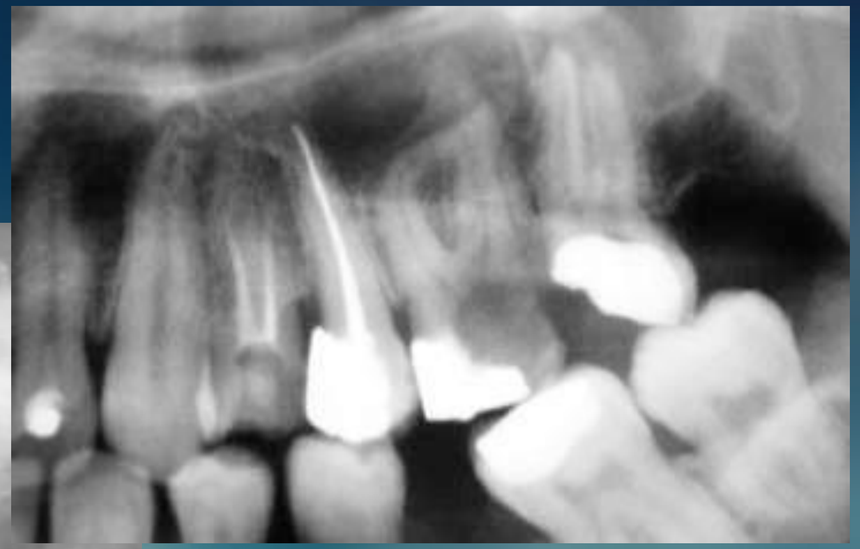

Bulbous roots or hypercementosis

Presence of old RCT

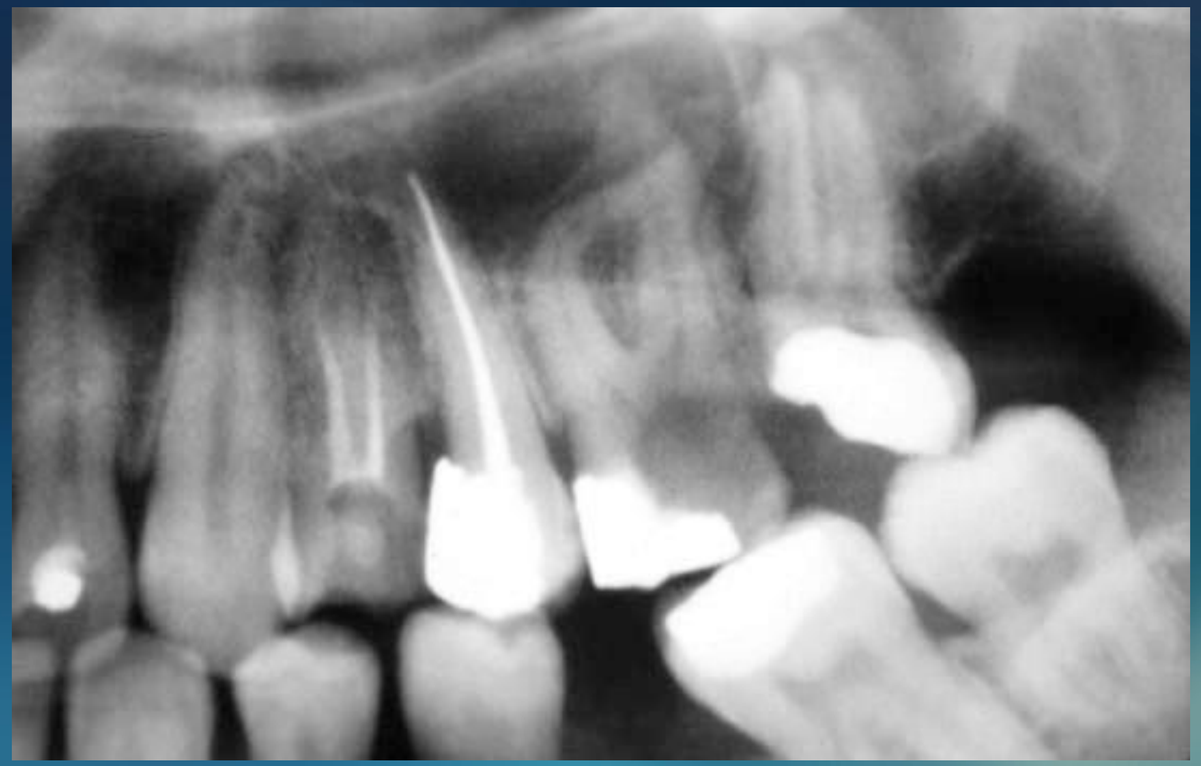

Protection of adjacent teeth

Presence of sclerotic bone or obscure PDL

Retained roots

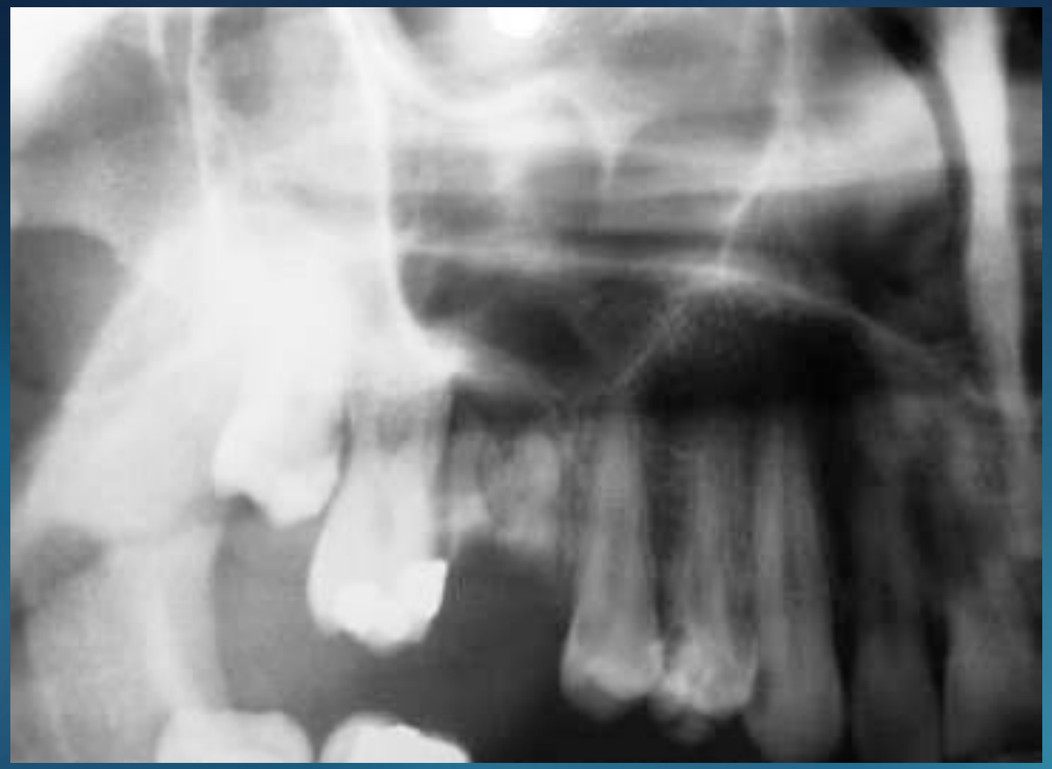

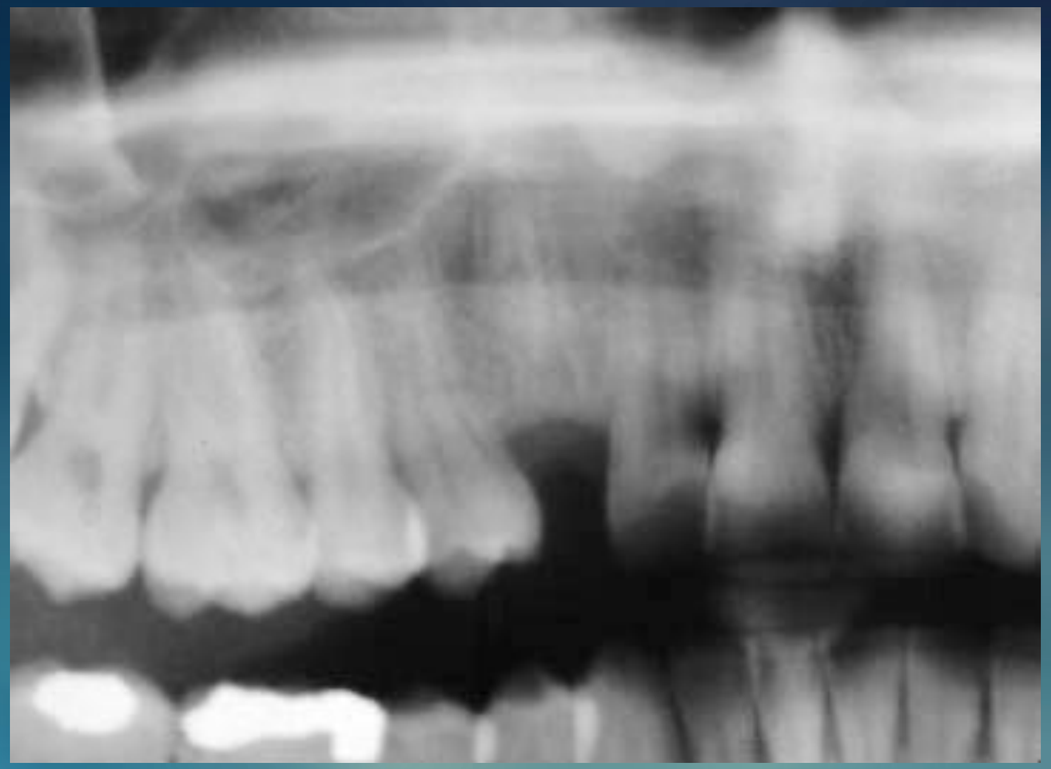

Surgical Dental Extractions

Definition

This technique often provides a time efficient procedure and a lesser traumatic operation than a bad simple extraction

If in doubt about extracting successfully with forceps – don't waste time

PLAN AND PERFORM OPEN EXTRACTION RIGHT FROM THE GET GO

Surgical Dental Extractions

Technique

1. Incision with 15 blade
2. Reflection of full thickness flap with #9 POE
3. Trough bone around the tooth +/- sectioning with 702 bur
4. Use purchase point to elevate dental segments
5. Curettage
6. Bone file
7. Copious irrigation
8. Suture flap (3-0 PGS)
9. Hemostasis

Flap

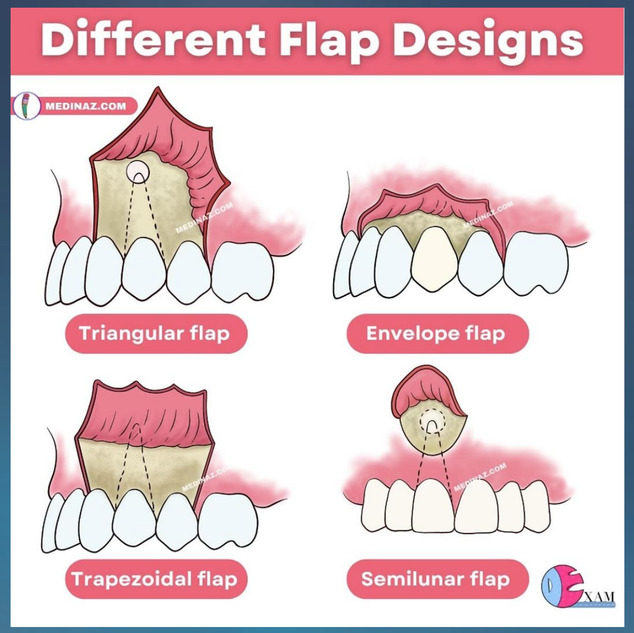

Purpose

- to get adequate visualization
- to provide access to the area (tooth/roots)

Proper Design

- full thickness broad based
- provide adequate exposure provide for suturing over solid bone respect anatomic structures

Flap

Full thickness

Incision through mucosa and periosteum down to bone

Periosteal elevator right under periosteum – on bone

Reflect periosteum with a sweeping motion staying on bone

Easy to reflect

Less surgical trauma

Less swelling / bleeding

Reduced post op discomfort

Flap

Broad base

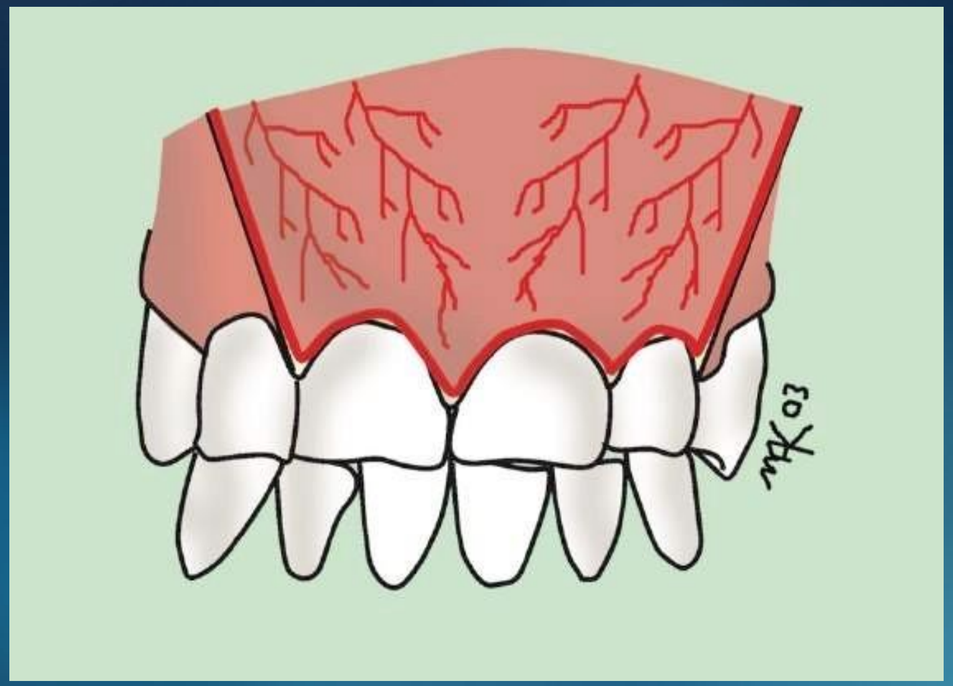

Flap

Provides adequate exposure

Extends one or two teeth mesial and one tooth distal of the area of surgery

Provides for room to use retractors

Allows for reflection without tearing the soft tissues

Small flap? Big mistake

Flap

Provides for suturing over solid bone

Ideally 3 mm from bone edge

If incision is over bone void the soft tissue will break down

Respects anatomic structures
- Mental nerve
- Lingual nerve
- Greater palatine vessels/nerve
- Incisive vessel/nerve

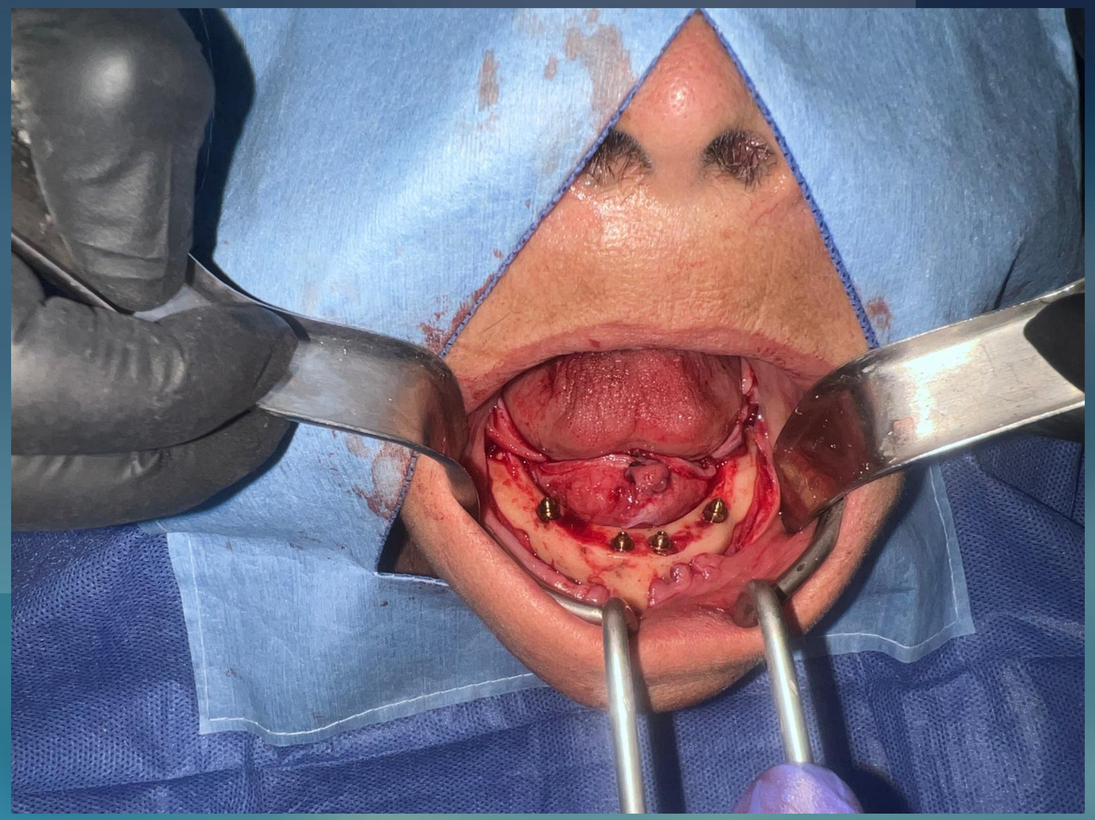

Envelope Flap

- Sulcular incision
- Relatively difficult to reflect
- Provides for minimum exposure, visualization and access
- Increased tension along flap prone to tear
- Easy re-approximation

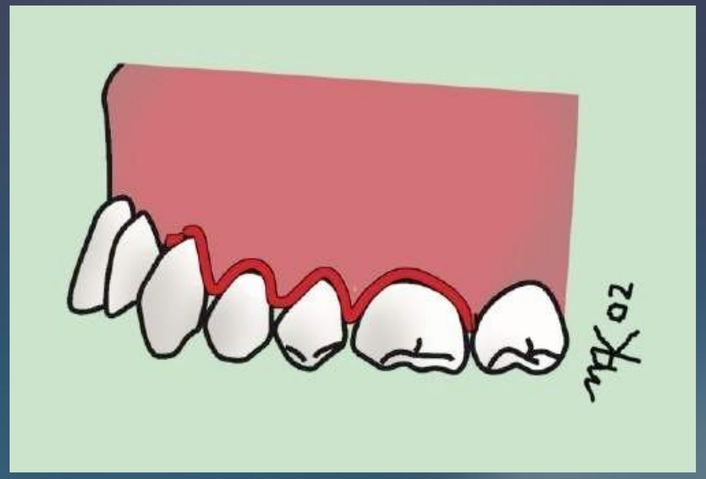

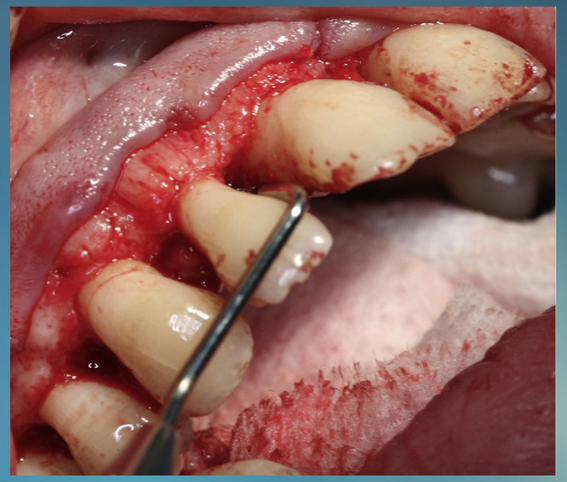

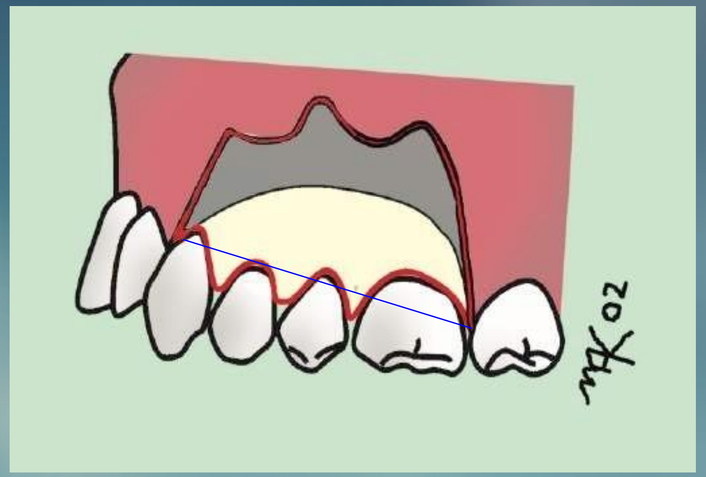

Flap

Types

Triangular Flap

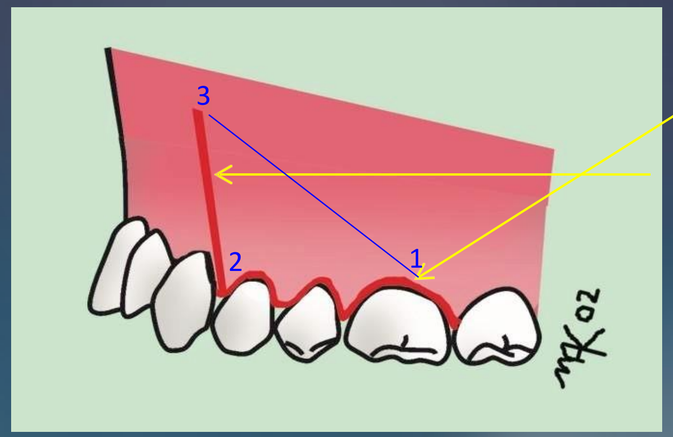

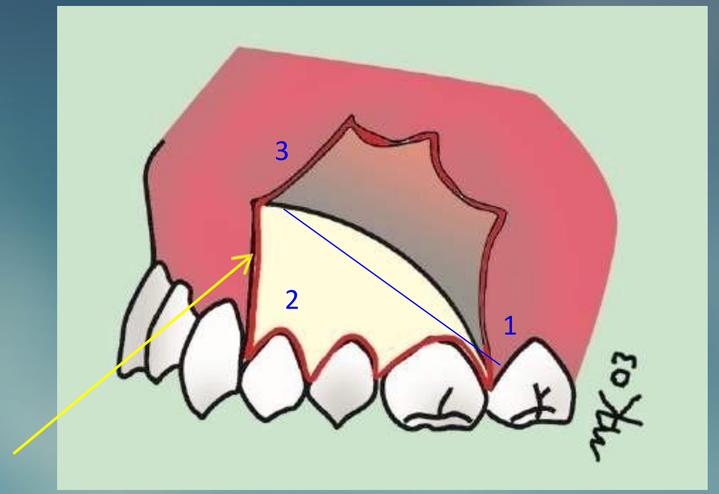

- Sulcular incision
- Releasing incision
- Easier to reflect
- Provides for good exposure, visualization and access
- Decreased tension along flap less prone to tear
- Easy re-approximation
- The higher the point 3 the more the apical exposure

  Increased post-op pain compared to envelope flap

Flap

Types

Trapezoidal Flap

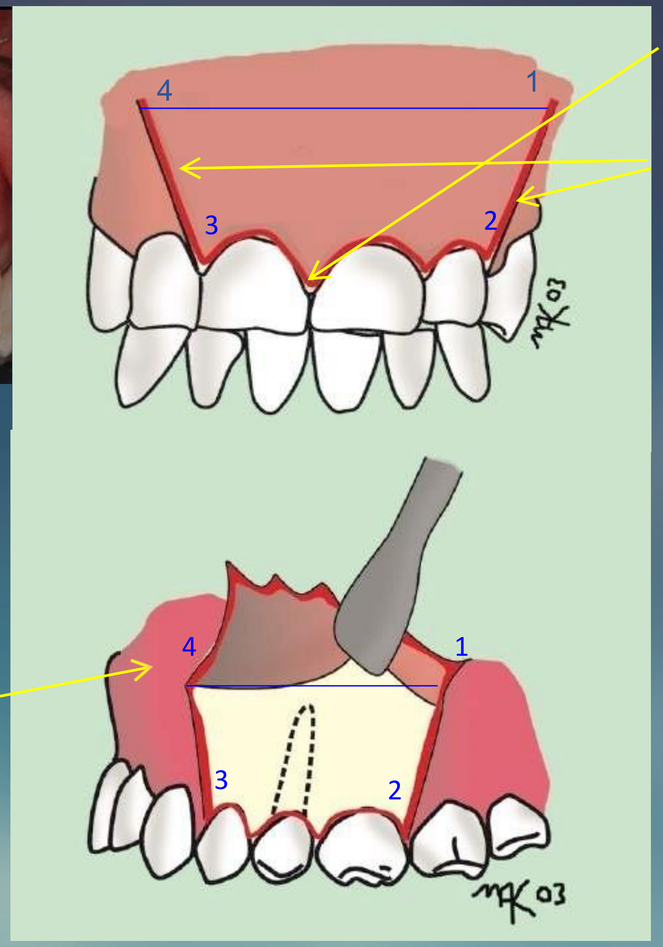

- Sulcular incision
- 2 Releasing incisions
- The flap will rotate around the line 1-4 Easiest to reflect
- Provides for excellent exposure, visualization and access
- No tension along flap
- not prone to tear
- Easy re-approximation
- Higher the points 1,4; more the apical extension

Semilunar Flap

- Mucosal incision and reflection
- Used for apical surgery and removal of small lesion from bone
- Easy to reflect
- Provides for good exposure, visualization and access
- No tension along flap, so not prone to tear
- Easy reapproximation

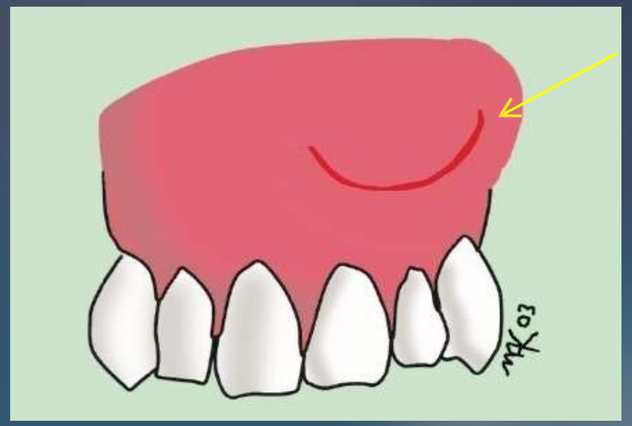

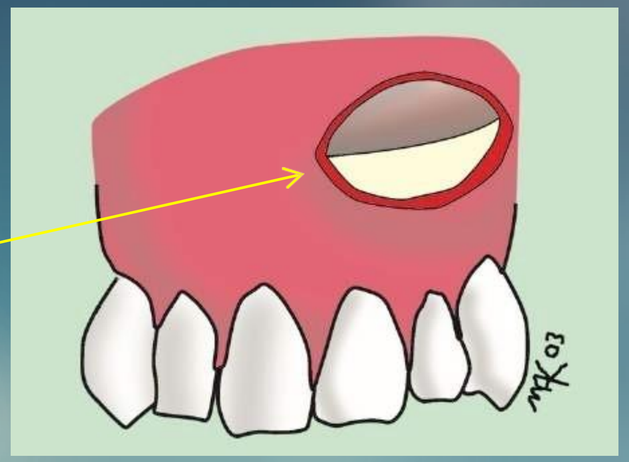

Surgical Extraction of Retained Root / Tooth with one root

Raise envelope flap

Create purchase point interproximally ONLY !!!

Loosen tooth with straight elevator

Grab and remove root with traction forceps

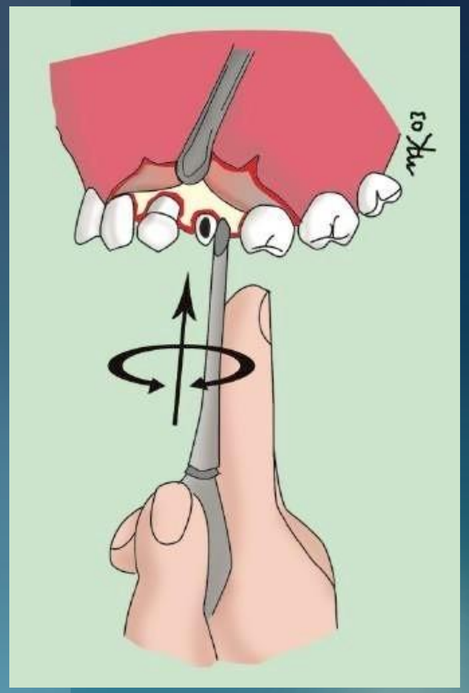

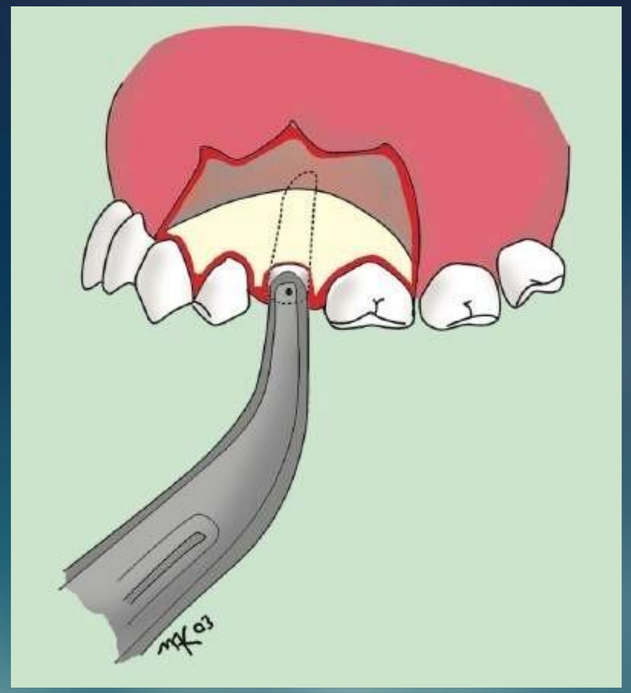

Surgical Extraction of Retained Root / Tooth with one root

If not successful,

Drill a trough in the interproximal along the long axis of the tooth

Buccal bone removal - The last resort!!!!

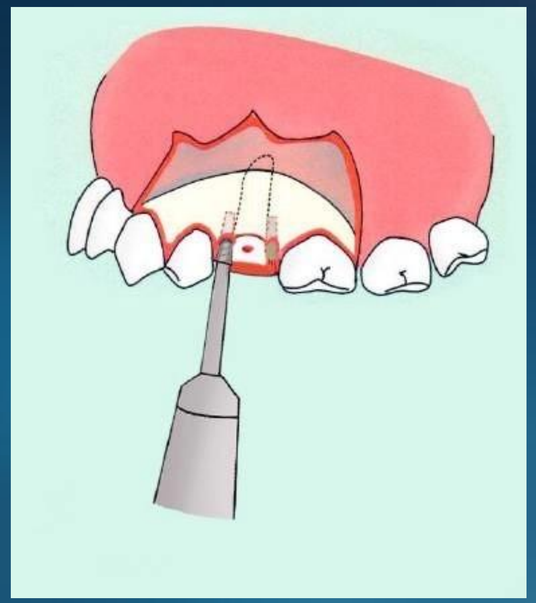

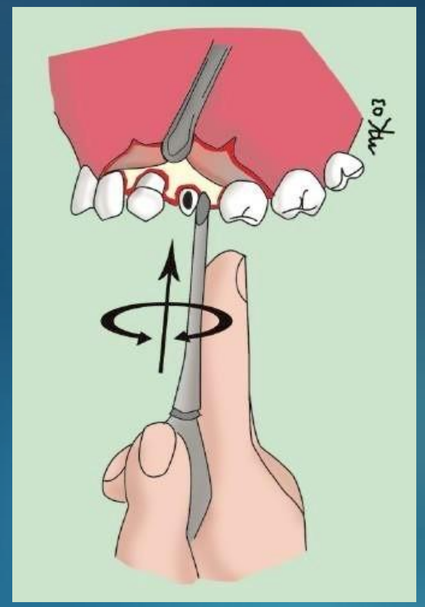

Surgical Extraction of Retained Root / Tooth with one root

For smaller apical segments

Raise triangular flap

Open bone window in the area of the apex Push root segment out

Preserve buccal bone!!!!

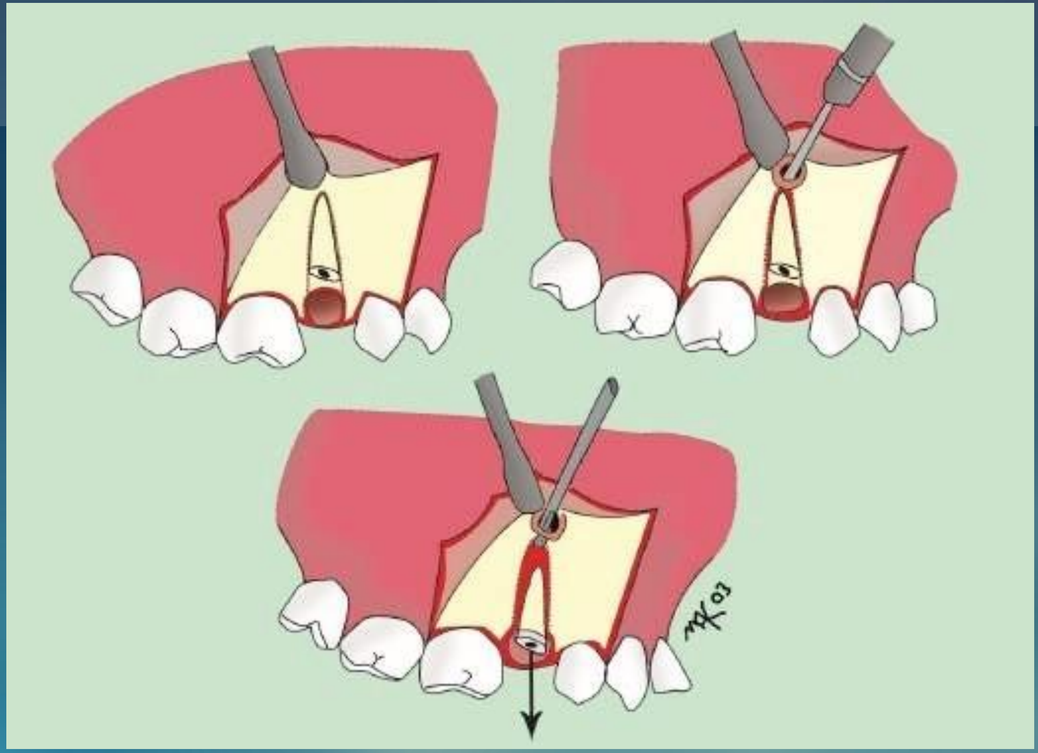

Surgical Extraction of Retained Root / Tooth with one root

For small roots completely embebed in bone

Raise semilunar flap

Open bone window in the area of the apex

Scoop root segment out

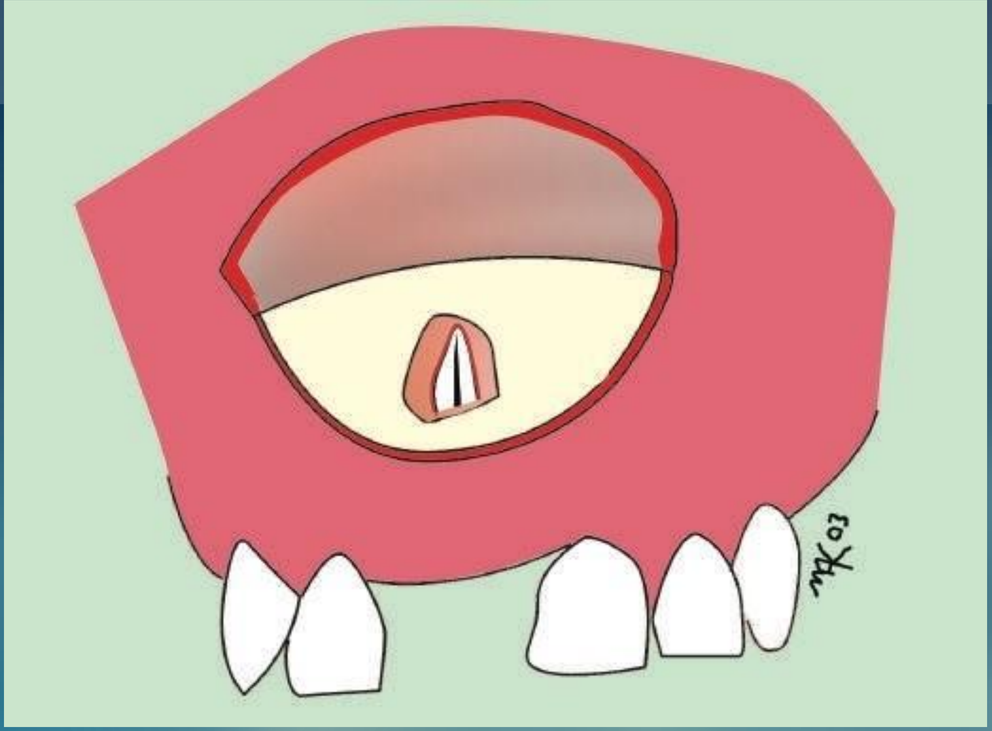

Surgical Extraction of Retained Root / Multirooted tooth

Raise envelope flap Separate roots

Remove interradicular bone

Elevate roots out separately

If no progress

Remove interproximal bone

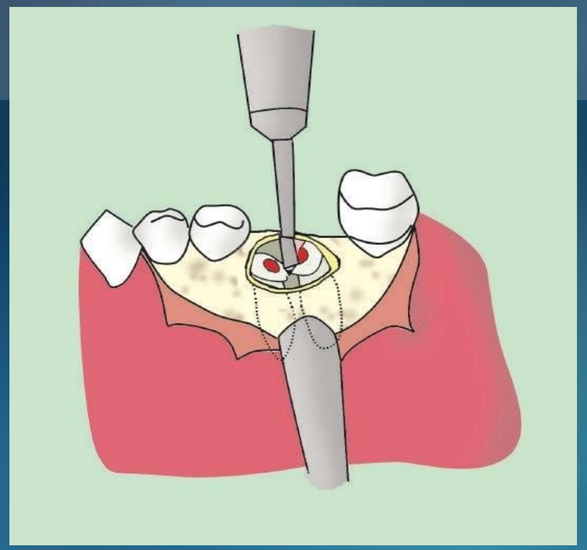

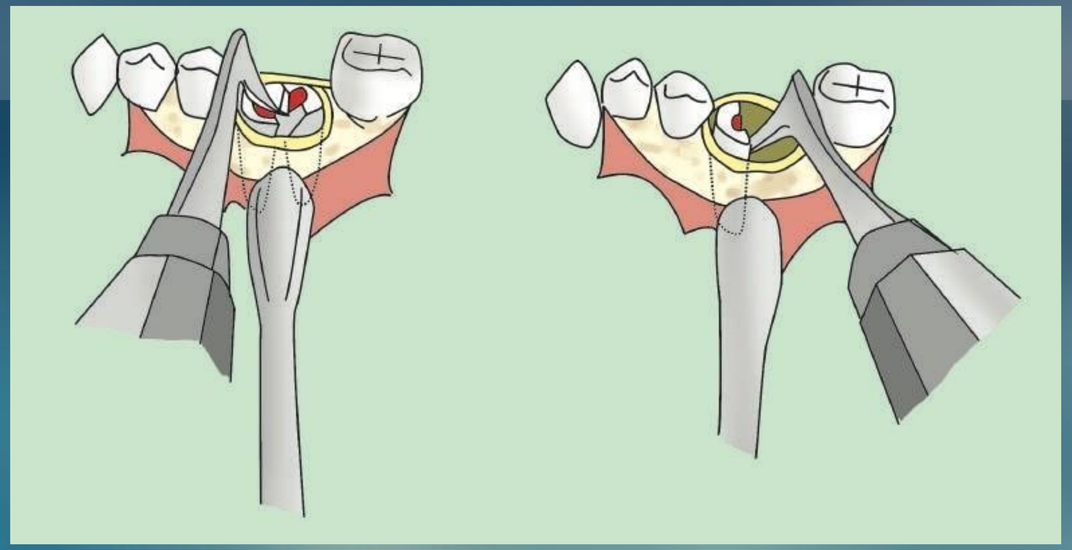

Surgical Extraction of Retained Root / Multirooted tooth

Raise envelope flap

Separate roots

Elevate roots out separately

If no progress

Remove interproximal bone

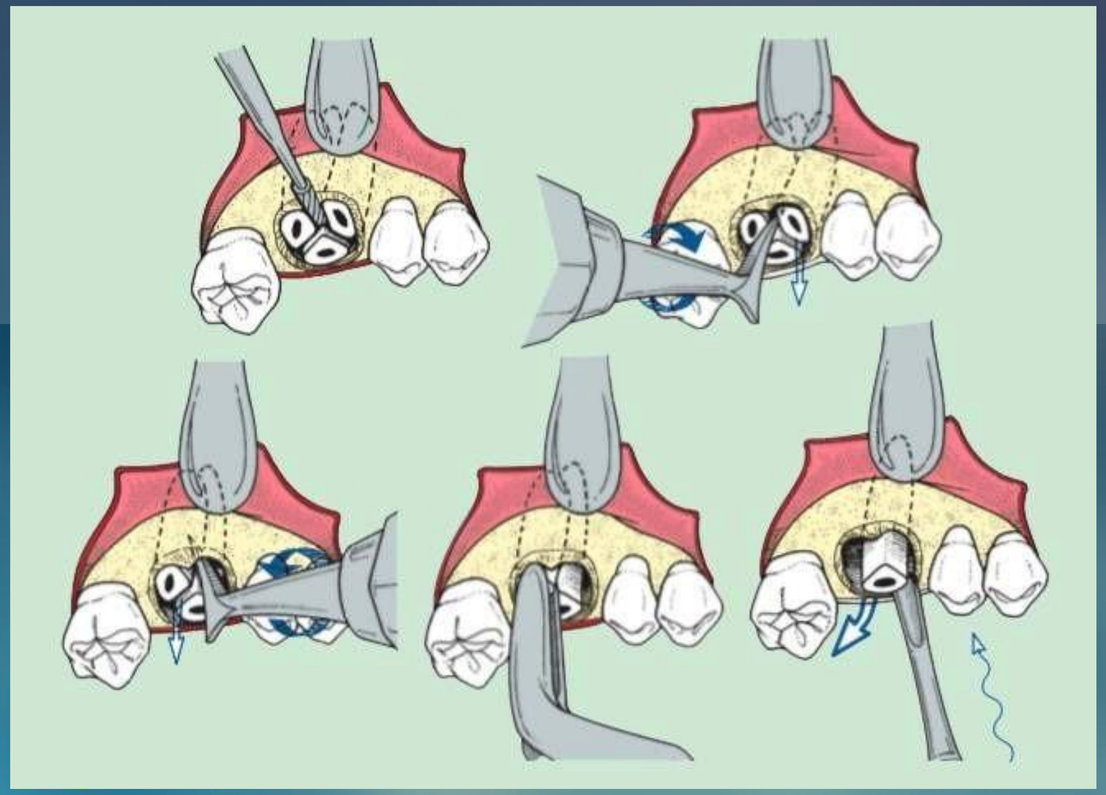

Surgical Dental Extractions

Debride when finished – curettage

Irrigation

Achieve hemostasis

Reapproximate / suture flap with interrupted sutures

Discharge patient with instructions

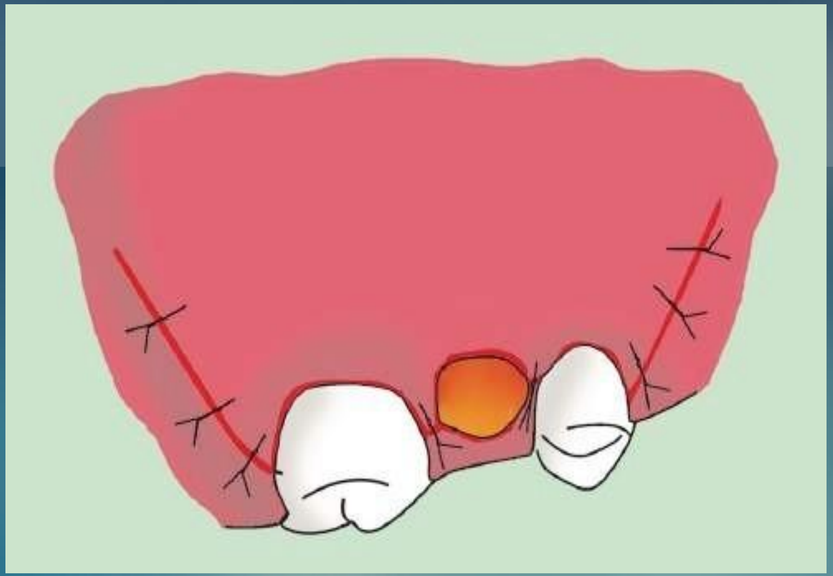

Extraction Socket

Inflammatory Phase	Bleeding Formation of clot Activation of immune system Proliferation of mesenchymal cells	THE FIRST 2-3 DAYS
	Proliferation of mesenchymal cells New vessel “sprouting” Formation of granulation tissue	BY THE END OF THE WEEK
Proliferative phase	Newly formed vessels develop a network Intense collagen production Osteoprogenitor cell activation Woven bone starts being laid down	IN 2 WEEKS
	Epithelial edges approximate Woven bone fills the whole space Covering epithelium gets keratinized	IN 4-8 WEEKS
Bone modelling	Change in shape of bone	IN 3 MONTHS (75% OF IT)
Bone remodelling	Conversion of woven to lamellar bone	MONTHS OR YEARS

Extraction Socket

Bone modelling

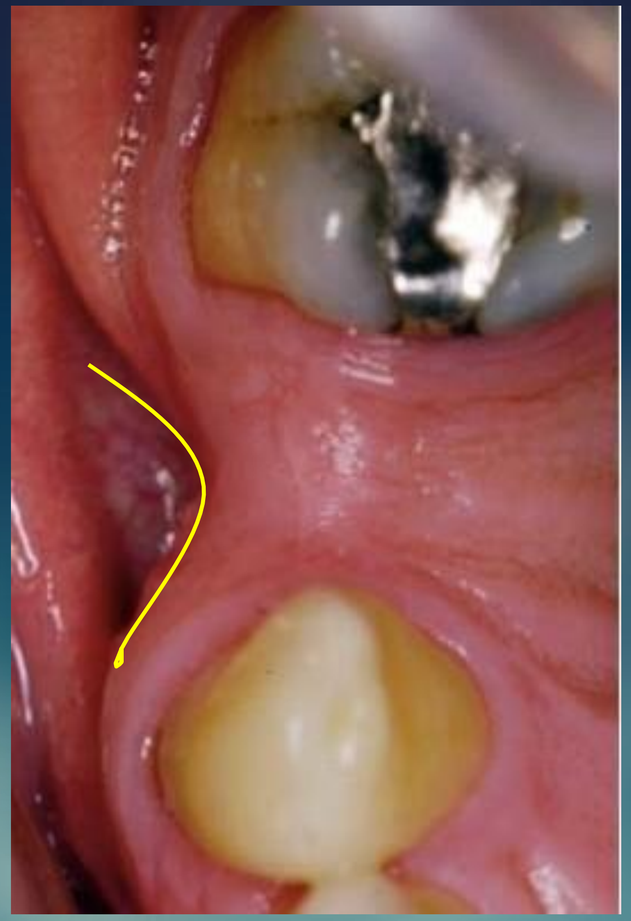

Extraction Socket

Bone modelling

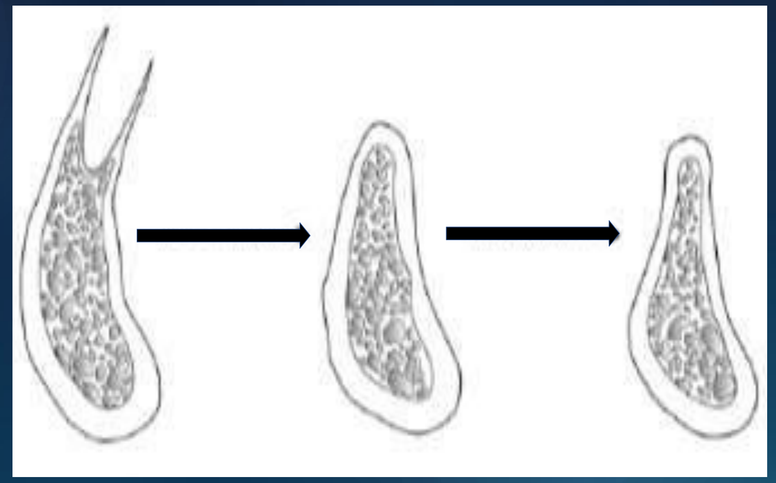

Why?

Class	Description
Class I	Dentate
Class II	Immediately post extraction
Class III	Well rounded ridge form, adequate in height and width
Class IV	Knife-edged ridge form, adequate in height and inadequate in width
Class V	Flat ridge form, inadequate in height and width
Class VI	Depressed ridge form, with some basilar loss evident

Cawood Howell Classification

Extraction Socket

Bone modelling

Thin buccal wall esp in anterior area PDL

Sharpey's Fibers entering alveolar bone- Bundle Bone

Does PDL survive the extraction? No

Would there be Bundle Bone in the area? No

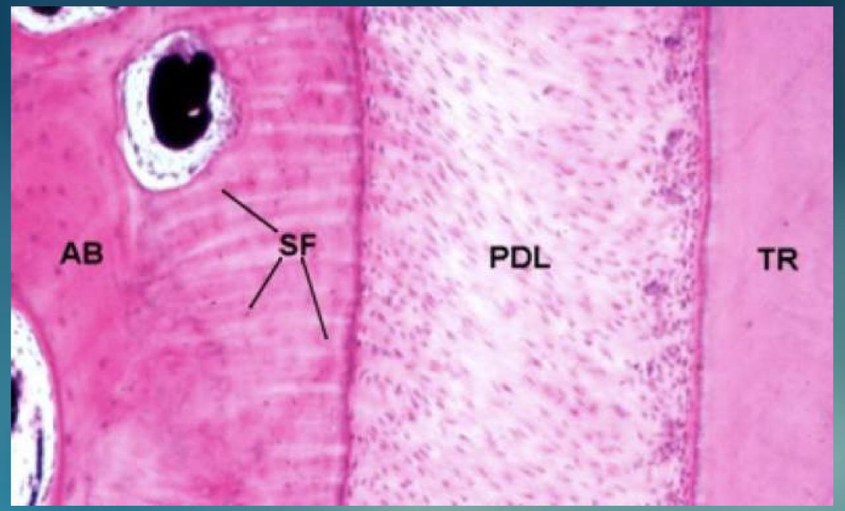

Extraction Socket

Bone modelling

Morphologic changes taking place in the area of alveolar process after extraction

Within 3 months after extraction, it will involve reduction of the vertical height of the socket

Will involve substantial reduction in the width of the socket up to 50% of the original width will be lost

Most of the loss will take place in the buccal aspect

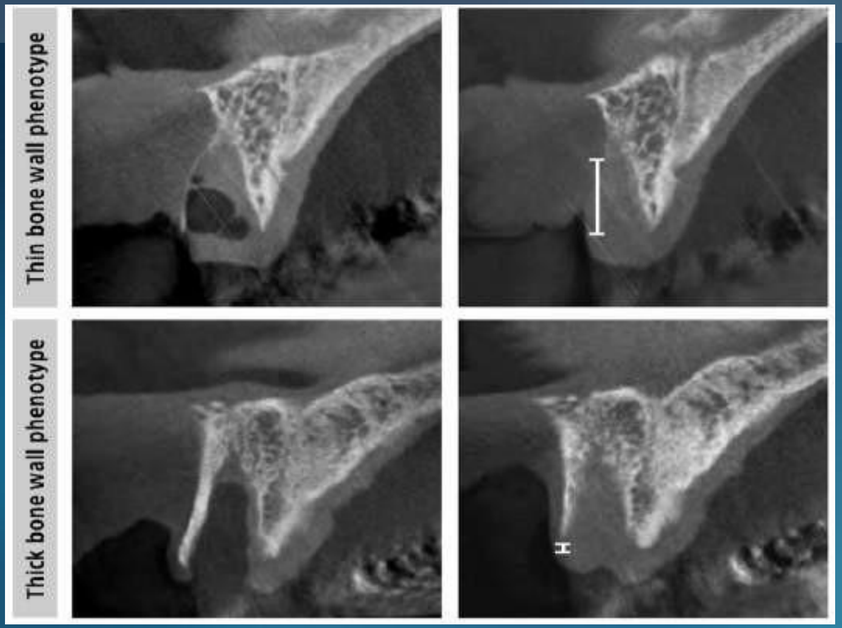

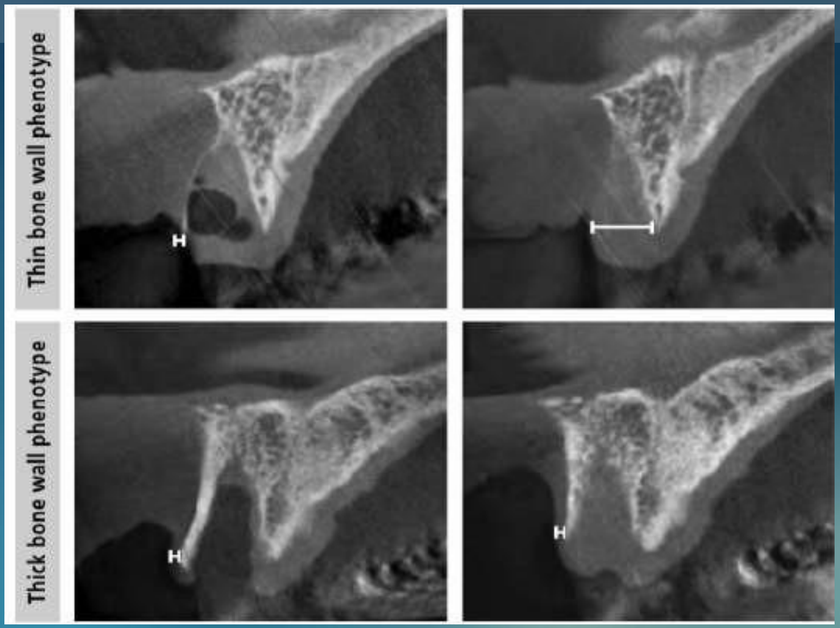

R
PaX-i

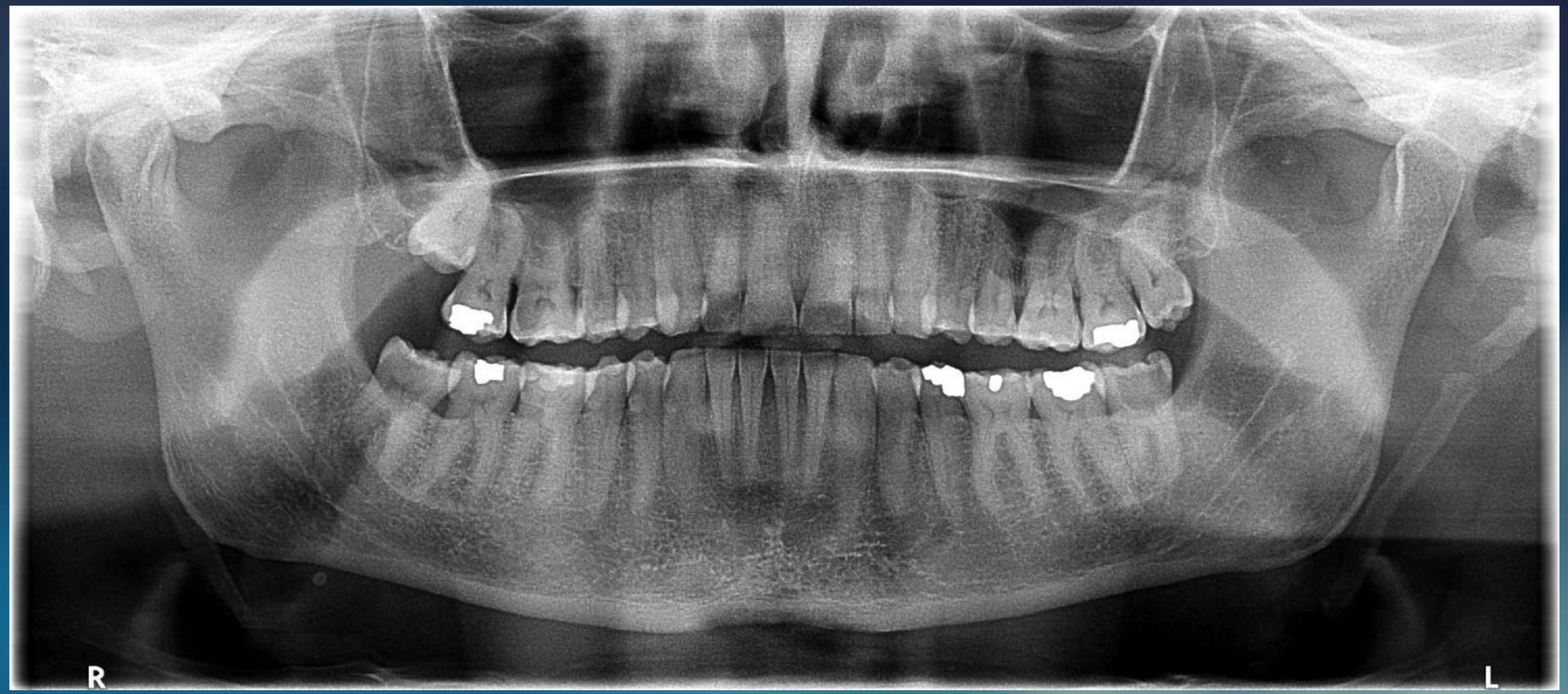
R
L

R
L

Thank you

Maria Franco Echevarria, MD, DMD, MSc, FRCDC
Assistant Professor. Undergraduate Program Director
Oral and Maxillofacial Surgery

Faculty of Dentistry
University of Toronto
maria.francoechevarria@utoronto.ca